

## CASE REPORT KALLMANN SYNDROME IN A 14-YEAR-OLD BOY

**Melisa Anggraeni, Made Arimbawa, IW Bikin Suryawan**

*Department of Child Health, Medical School,  
Udayana University, Sanglah Hospital, Denpasar, Bali*

### ABSTRACT

Kallmann syndrome is a combination of hypogonadotropic-hypogonadism due to gonadotropine releasing hormone (GnRH) deficiency with anosmia or hyposmia. Magnetic resonance imaging (MRI) reveals hypoplasia or aplasia of the olfactory bulbs. The incidence is estimated at 1 in 10.000 and 50.000 males and females respectively. The main clinical features consists of the absence of spontaneous puberty, partial or total loss of the sense of smell (anosmia). In this case report, we describe a 14 year old boy with Kallmann syndrome who was refferred with delayed puberty and lack of smell function. Physical examination revealed Tanner stage I and proven anosmia from olfactory test. Laboratory test showed low titer of testosterone. Testicular ultrasonography (USG) revealed small testicles. Treatment of this particular patient was with a 25 mg of intramuscular testosterone injection and were then increased by 25 mg every two weeks. Proper management of patients with Kallmann syndrome usually allows them to attain normal reproductive health [MEDICINA 2013;44:56-61]

*Keywords : Kallmann syndrome, hypogonadotropic-hypogonadism, anosmia*

## SINDROM KALLMANN PADA ANAK LAKI-LAKI USIA 14 TAHUN

**Melisa Anggraeni, Made Arimbawa, IW Bikin Suryawan**

*Bagian/SMF Ilmu Kesehatan Anak, Fakultas Kedokteran Universitas Udayana/Rumah Sakit Umum  
Pusat Sanglah Denpasar*

### ABSTRAK

Sindrom Kallmann adalah suatu sindrom dengan gejala gabungan defisiensi hormon gonadotropin dan anosmia atau hiposmia, dimana terdapat gambaran hipoplasia atau aplasia bulbus olfaktorius dalam pemeriksaan *magnetic resonance imaging (MRI)*. Insidennya berkisar antara 1: 10.000 pada laki-laki dan 1:50.000 pada perempuan. Manifestasi klinisnya berupa tidak munculnya tanda-tanda pubertas dan hilang atau berkurangnya daya penciuman. Pada kasus ini, laki-laki, 14 tahun dengan keluhan tidak ada tanda pubertas dan kurangnya daya penciuman. Pemeriksaan fisik didapatkan genitalia Tanner derajat I (tidak sesuai dengan usia pasien) dan dari uji penciuman didapatkan pasien terbukti anosmia. Dari pemeriksaan laboratorium didapatkan kadar testosterone rendah. Hasil USG (ultrasonografi) menunjukkan ukuran testis kecil. Pasien diberikan terapi dengan injeksi testosterone 25 mg intramuskular dan dinaikkan 25 mg setiap 2 minggu. Dengan terapi yang adekuat diharapkan gangguan reproduksi dapat teratasi. [MEDICINA 2013;44:56-61]

*Kata kunci : sindrom Kallmann, hipogonadotropik-hipogonadism, anosmia*

## INTRODUCTION

Kallmann syndrome (KS) is defined as the association of olfactory deficit with irreversible congenital isolated gonadotropin deficiency (IHH).<sup>1</sup> The syndrome was first identified by an American geneticist, Franz Kallmann who at the time had been studying the occurrence of hypogonadism accompanied by anosmia in three affected families, who apparently showed anosmia and hypogonadism in all affected individuals leading to a conclusion that the syndrome were hereditary.<sup>2</sup> In the 1950's an anatomist from Switzerland, De Morsier further documented the disease by describing the underdevelopment or absence of the olfactory bulbs and tracts in several male patients with accompanying hypogonadism. Some years later, the hypogonadism was described as due to the deficiency of gonadotropin-releasing hormone (GnRH) secretion.<sup>3</sup>

The prevalence of KS is unknown.<sup>2</sup> It has been roughly estimated at one in 8000 boys which is relatively higher than previously thought to be 1: 80,000 boys. However in girls, its prevalence is thought to be five times lower at approximately 1:40,000-70,000 which is probably due to underestimation in relation to the mild hypogonadism that usually affects females. Moreover primary amenorrhea in females often remains unexplored.<sup>4</sup>

In KS, anosmia is usually associated with abnormalities or even complete absence of

the olfactory bulbs and sulcus demonstrated by magnetic resonance imaging (MRI).<sup>2</sup> Unless being exposed to physiological levels of gonadal steroids, KS patients cannot complete puberty and thus requiring lifelong hormonal replacement therapy to achieve and maintain secondary sexual characteristics and bone mineral density.<sup>5</sup> We reported a fourteen year old male who reveals classical morphological features of KS.

## CASE REPORT

AS, a 14 year old boy referred to the endocrinology outpatient clinic with a chief complaint of a small penis. The parent brought their son to a pediatrician because they had concerns on the size of their sons penis relative to his age, which were realized five years ago with limited testicular enlargement without pubic hair. The patient had an issue of erectile dysfunction which was noted by a short duration of less than five minutes of erection while viewing adult materials. The patient has no previous history of masturbation and thus never had experienced ejaculation. There was no complaints of urinary function.

The patient had also complaints regarding his smelling function which was described as not being able to smell anything during his life thus making him unable to differentiate the smell of perfumes or fecal odor. There were no history of hormonal therapy, narcotic substance abuse, steroids nor

chemotherapy and lastly no history of trauma.

The patient has a 20 year old sister who had experienced menarche at age 11, normal breast and pubic hair development with regular menstrual cycles. Neither of his parents has had symptoms of sexual organ dysfunction nor delayed puberty. There were no history of consanguinity nor induced fertility.

Physical examination revealed an alert and active boy. Pulse was 98 bpm, respiratory rate 22 breaths per minute, axillary temperature 36.8°C. Body weight, height, and upper arm circumference were 55 kg (50<sup>th</sup>-75<sup>th</sup> percentile, CDC 2000), 164 cm (50<sup>th</sup> percentile, CDC 2000) and 25 cm respectively. Ideal body weight was 51 kg which according to the Waterlow criteria, the patient reveals a 93% nutritional status (well-nourished). His high potential genetic was 168.5 ± 8.5cm with an arm span of 160 cm. Upper/lower segment ratio was 1.1.

The hair was fine and black in color without any signs of dysmorphic facial features. Conjunctiva and pupil reflexes appeared normal. Facial appearance revealed no facial hair growth. No voice changes had been noted and neck examination was normal. There were also no palpable cervical spine nodes identified. We also performed an ENT (ear, nose and throat) examination with a modified sniffing test designed by our department incorporating odors that may be identified among all social classes of the population such as coffee and tobacco which

he could not identify at all.

Urogenital examination revealed no hypospadias with penile length of 2.8 cm, left and right testicular volume of 1.5 and 1.5ml (with Prader orchidometer), respectively. Body and pubic hair were absent leading to Tanner stage I (Figure 1).

Based on interviews and physical examination we concluded our working diagnosis as hypogonadotropic hypogonadism with differential diagnosis of constitutional delay of growth and puberty and hypergonadotropic hypogonadism. Further diagnostic planning were complete blood count, luteinizing hormone (LH), follicle stimulating hormone (FSH) and testosterone serum, testicular ultrasound, bone age measurement, consultation with ear, nose, and throat (ENT) surgery department for olfactory test, MRI, and chromosomal analyses.

The results of LH, FSH, and testosterone serum concentration were 0.27 mIU/ml (N: 0.4-7.0), 0.90 mIU/ml (N: 0.81-8.18) and 5 ng/dl (N: 220-800), respectively. Testicular sonography revealed small size: 1.67 x 0.8 x 1.28 cm. Both testicles had normal echo parenchym without nodules/calcification. Conclusion was right and left testicles within the scrotum with small size (Figure 2). An X-ray of the hand (in anterior, posterior and lateral views) revealed the total size of metacarpal of digit II was 8 mm consistent with the bone age appropriate for a 14 year old child (normal bone

age) (Figure 3).

Ear, nose, and throat surgery department revealed results of unresponsive with simple and intravenous

olfactory tests consistent with the conclusion of anosmia. Magnetic resonance imaging test revealed no apparent olfactory bulbs regarding the

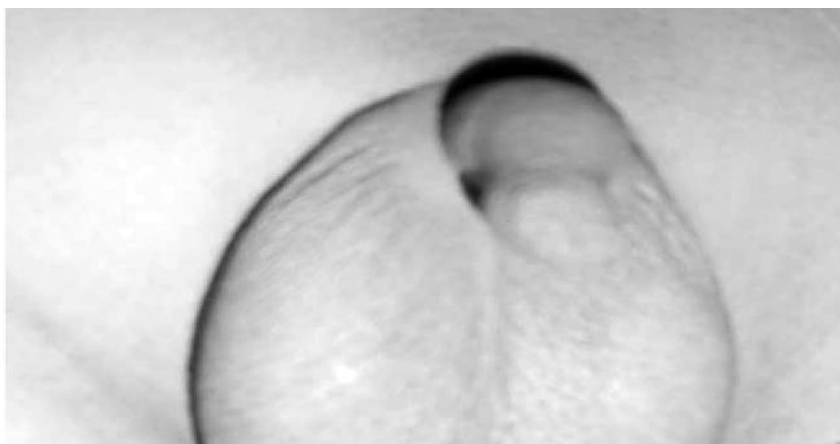

Figure 1. Micropenis and no pubic hair.

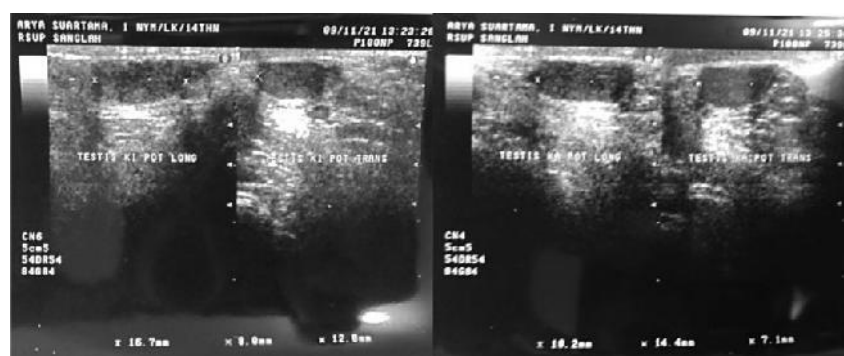


Figure 2. Testicular USG: right and left testis inside scrotum with small size.

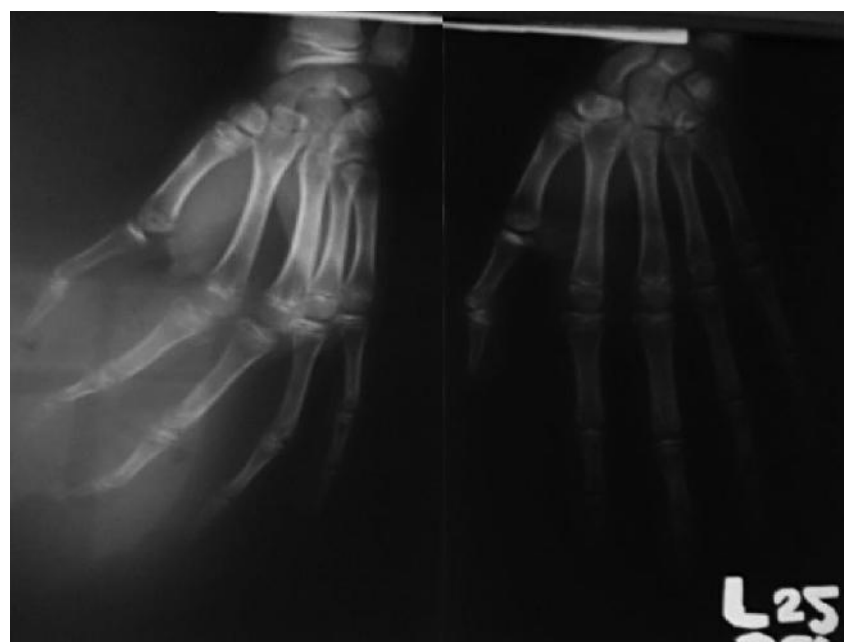

Figure 3. Rontgenogram of left hand: bone age was appropriate for 14 years old child.

limitation of the machine. Chromosomal analyses of KAL and FGFR was unable to be performed due to the lack of equipment.

Regarding all the data above, we concluded that the patient suffered from hypogonadal hypogonadotropic deficiency with anosmia namely Kallmann syndrome. Management of this patient was by the administration of testosterone 25 mg by intramuscular injection, which were gradually increased by 25 mg every two weeks. This patient also required testosterone replacement therapy to achieve and maintain normal bone, fertility, and sexual function.

## DISCUSSION

Patients with KS usually seek medical attention because of delayed puberty or incomplete sexual development.<sup>2,6</sup> Anosmia or hyposmia are present in 80% of the patients and establishes the diagnosis of the syndrome in individuals with isolated gonadotropin deficiency. Pre pubertal testicles, micropenis, and cryptorchidism are usually seen. Male patients with KS present themselves with decreased libido, erectile dysfunction, decreased muscle strength, and diminished aggressiveness while females will present the disease with amenorrhea or dyspareunia.<sup>1,7</sup> Magnetic resonance imaging of the brain in patients with KS by both coronal and axial views will demonstrate absence of the olfactory bulbs and sulci, either

laterally or bilaterally. Shallow olfactory sulci is found in 90% of cases. An MRI may assist in excluding hypothalamic and pituitary lesions in patients with hypogonadism.<sup>8</sup>

In practice, special attention should be paid to testicular volume, both at diagnosis and follow up of these patients since it indicates an increase in gonadotropin secretion. In addition, periodical interruption of testosterone replacement therapy and reassessment of gonadal function of these patients may be desirable in order to avoid unnecessary hormone replacement and inappropriate reproductive prognosis.<sup>6</sup>

We presented our case, a 14 year old male with delayed puberty, micro penis and small testicles (Tanner st I). Results of testicular sonography revealed small size of both testicles. Sniffing and olfactory tests revealed no response meaning that the patient has anosmia. Magnetic resonance imaging was unsatisfactory due to limitation of the machine. Arm span, upper to lower body ratio were normal.

Five causal genes have been identified to date namely KAL1, KAL2, FGFR1, PROKR2, and FGF8.<sup>9</sup> PROKR2 or PROK2 encoding prokineticin receptor-2 and prokineticin-2 have been detected in approximately 9% of KS patients.<sup>10</sup> Many cases are sporadic, representing new mutations. Familial cases may be autosomal dominant, autosomal recessive or X-linked.<sup>11</sup> The X linked form may be associated with mutations in the KAL gene (Xp22.3)

which encodes anosmin-1, a neural cell adhesion molecule necessary for the migration of olfactory neuron axons and gonadotropin-releasing hormone (GnRH) synthesising neurons toward their final destination.<sup>12</sup> Our case presented with no history of family members having either delayed puberty, anosmia nor both. There were no consanguinity concluding that this case may be sporadic. No chromosomal examination were performed due to the limited resources.

Hypogonadotropic hypogonadism is characterized by inappropriately low serum concentrations of LH, FSH in the setting of hypogonadism. Hypogonadotropic hypogonadism (HH) is most frequently acquired and may be caused by a number of pathological processes but may also occur as part of various congenital syndromes.<sup>13</sup> Isolated GnRH deficiency (IGD) is a relatively rare but important subset of HH caused by impaired gonadotropin release in the setting of normal pituitary anatomy and function and in the absence of secondary causes of HH. Isolated GnRH deficiency is characterized by low or normal concentration of LH and FSH in the setting of low circulating concentrations of sex steroids (total testosterone <100ng/dl; estradiol <50 pg/ml).<sup>14</sup> Our case presented with low serum concentration of LH, FSH, and testosterone.

The treatment of KS is hypogonadism therapy. The aim is to initiate virilization or breast development then

secondly to achieve fertility.<sup>5</sup> Hormone replacement therapy with testosterone for males and a combination of estrogen and progesterones for females aims to stimulate secondary sexual characteristics. For those desiring fertility, either gonadotropins or pulsatile GnRH can be used to obtain testicular growth and sperm production in males or ovulation in females. Both treatment restore fertility in a vast majority of affected individuals. It is still unknown whether transient hormone replacement therapy in affected male infants to stimulate the postnatal surge in gonadotropins could later have an impact on their sexual life and reproductive prognosis.<sup>14</sup> To induce and maintain secondary sexual characteristics is by gradually increasing the doses of gonadal steroids (testosterone or hCG injection in males; estrogens and progestin in females). To stimulate spermatogenesis, gonadotropin therapy (hCG and hMG or recombinant FSH or pulsatile GnRH) may be administered. In vitro fertilization is an option if spermatogenesis is achieved but infertility persists. There is currently no treatment for olfactory deficit.<sup>11</sup> Our patient was treated with 25 mg of testosterone by intramuscular injection, gradually increasing the dose by 25 mg every two weeks.

The reversal of hypogonadism in KS indicates that a population of GnRH neurons have successfully migrated to the hypothalamus and established functional connection with other neurons

as well as with vessels in the median eminence. Theoretically, variations in the amount of neurons effectively reaching the hypothalamus and establishing adequate connections could explain the broad spectrum of gonadal function in KS, including severe hypogonadism, delayed puberty and reversible hypogonadism.<sup>13</sup> The possibility of patients with reversible KS represent an extreme degree of pubertal delay that would eventually enter puberty if left untreated cannot be ruled out. Delayed puberty with or without anosmia is known to occur in other family members of KS patients sharing the same mutation. On the other hand, testosterone replacement therapy could play a role in reversible KS.<sup>12</sup> Our case shows that reversible KS may occur in the future due to the response to testosterone replacement therapy. Follow up of therapy is a must especially focusing on testicular enlargement and total serum testosterone levels to avoid unnecessary hormone replacement.

#### SUMMARY

Our case demonstrate a 14 year old male with micropenis and small testicles (Tanner st I), regarding the findings derived from interviews, physical examination, low concentration of serum LH, FSH, and testosterone with the addition of anosmia, we may conclude that this patient has features of KS. Treatment of this particular patient was

with a 25 mg of intramuscular testosterone injection and were then increased by 25 mg every two weeks. We hope that reversible KS may occur in our patient due to the response to testosterone replacement therapy.

#### REFERENCES

1. Dode C, Hardelin JP. Kallman syndrome. *Eur J Hum Genet.* 2009;17:139–46.
2. Quinton R, Cheow HK, Tymms HK, Bouloux PMG, Jacobs HS. Kallmann's syndrome: is it always for life? *Clin Endocrinol.* 1999;50:481–5.
3. Ribeiro RS, Vieira TC, Abucham J. Case report: Reversible Kallmann syndrome: report the first case with a KAL1 mutation and literatur review. *Eur J Endocrinol.* 2007;156:285–90.
4. Abujbara MA, Hammamy HA, Jarrah NS, Shegem NS, Ajlouni KM. Clinical and inheritance profiles of Kallmann syndrome in Jordan. *Reproductive Health.* 2004;1:5-8.
5. Hardelin JP, Dode C. Practical genetics: Kallmann syndrome. *Eur J Hum Genet.* 2009;17:139–46.
6. Bourguignon JP. Delayed puberty and hypogonadism. In: Bertrand J, Rappaport R, Sizonenko PC, editors. *Pediatric endocrinology.* Second edition. Philadelphia: Waverly Company; 1992. p. 404-17.

7. Hardelin JP. Kallmann syndrome: towards molecular pathogenesis. *Mol Cell Endocrinol.* 2004;179:75-81.
8. Christensen RB. Idiopathic Hypogonadotropic Hypogonadism with Anosmia. *The Endocrinologist.* 1992;2:332-40.
9. Archerman JC. Delayed puberty. In: *Petsco OH, Eugster EA, editors. Pediatric endocrinology: mechanisms, manifestations, and management.* Philadelphia: Lippincott Williams & Wilkins; 2004. p. 334-50.
10. Davidson TM, Murphy C. Rapid clinical evaluation of anosmia: The alcohol sniff test. *Arch Otolaryngol Head Neck Surg.* 1997;123:591-4.
11. Oliveira LMB, Seminara SB, Beranova M, Hayes FJ, Valkenburgh SB, Ellena V, *et al.* The importance of autosomal genes in Kallmann syndrome: Genotype-phenotype correlations and neuroendocrine characteristics. *J Clin Endocrinol Metab.* 2001;86:1532-8.
12. Quinton R, Duke VM, Robertson A, Kirk JMW, Matfin G, David J, *et al.* Idiopathic gonadotrophin deficiency: Genetic questions addressed through phenotypic characterization. *Clin Endocrinol.* 2001;55:163-74.
13. Raivio T, Falardeau J, Dwyer A, Quinton R, Hayes FJ, Pater W, *et al.* Reversal of idiopathic hypogonadotropic hypogonadism. *N Engl J Med.* 2007;357:863-73.
14. Waal, HAD. Application of gonadotropin releasing hormone in hypogonadotropic hypogonadism-diagnostic and therapeutic aspects. *Eur J Endocrinol.* 2004;151: U89-94.