

The Change in External Genital and Estrogen Level of Bali Cattle During Estrus

Desak Nyoman Dewi Indira Laksmi¹, I Gusti Ngurah Bagus Trilaksana²

¹Veterinary Reproduction and Obstetric laboratory, Veterinary Clinical Department, Faculty of Veterinary Medicine, Udayana University, Bali, Indonesia.

Email dewiindira@unud.ac.id

²Veterinary Reproduction and Obstetric laboratory, Veterinary Clinical Department, Faculty of Veterinary Medicine, Udayana University., Bali, Indonesia.

Email: agunglaksana@unud.ac.id

Corresponding Author: dewiindira@unud.ac.id

Abstract. The successful application of reproductive technology requires knowledge of estrus cycle and the ability to detect estrus of Bali cattle. Estrus in cattle lasts for 8-30 hours showed by the acceptance of males for copulation. In this phase, estrogen levels reach maximum levels. High levels of estrogen cause signs of estrus, and changes in the reproductive organs. This study aims to determine estrogen levels during estrus and external genital changes during estrus. This research was an observational analytic study with cross-sectional study design. The samples used in this study were Bali cattle during estrus. The samples had healthy status without any signs of disease. Blood samples were taken through the jugular vein were then centrifuged to obtain serum. The obtained serum was examined for estrogen hormone levels. Mechanical measurements of hormone levels checked by using the Direct Elisa, Double Antibody Sandwich. Blood samples were collected from several SIMANTRI in Mengwi District, Badung Regency. The results showed in Bali cattle external genitals change when estrus, namely redness of the vaginal mucosa, discharge from the vagina and swelling of the vulva. While estrogen levels when estrus is 69.80 pg/ ml. Further research needs to be continued to measure the quality of ovulation after estrus.

Keywords: Changes of external genitals, estrogen levels, estrus, bali cattle

I. INTRODUCTION

Bali cattle is one of Indonesian's native livestock genetic resources. Bali cattle is a domesticated wild bull, *Bos sondaicus* with its habitat in Bali Island. The specific phenotype form of Bali cattle is moderately sized, deep chest, slender feet, brick-red skin, black muzzle, nails, and tail-end. The legs under the carpal and

tarsal joints are white. White color can also be found in oval-shaped rump (white mirror). The upper part of the back is always covered by black-lined fur (eel line). Bulls had darker color compared to cows. The color of the bull usually changes from brick-red to dark-brown or black after they reached genital maturity.

Black can turn to dark brown or brick-red if the bull is castrated [1].

The development of Bali cattle population achieved pleasing progress. This can be observed from the distribution location in most Indonesian regions concentrated in Bali, West Nusa Tenggara, East Nusa Tenggara, South Sulawesi, South Kalimantan, Lampung, and South Sumatera with a population of 3.2-3.3 million cows. Bali cattle as germplasm of local Indonesian cattle has the best characteristics and production quality in Indonesia [2].

Several advantages owned by Bali cattle compared to other Indonesian local cattle are the ability to produce excellent meat and carcass quality with a higher percentage of the carcass. High production percentage of carcass can reach 60%, thus suitable to be developed as beef cattle [3]. Feed quality highly determines beef quality. In young cattle who were given concentrates, the quality of beef produced is the same as imported beef quality. As beef cattle, Bali cattle is resistant to hot weather. The body of Bali cattle has small water crossing system with big water reservoir (means that the adaptation to heat tolerance of tropical environment is very good). Other than that, it is also reported that this type of cattle has higher digestibility of nitrogen in low nutrition

forages compared to other types of cattle [4].

Bali cattle have an advantage compared to other local cattle, due to high fertility which reached 90%, pregnancy rate of 80-90%, high birth rate (more than 80%). Furthermore, the percentage of Bali cattle carcass is quite high (56%); its fat had low cholesterol with high growth compensation [4]. Regarding the reproductive performance of Bali cattle, the efforts needed are (1) increasing conception rate), (2) shortening calving interval, (3) reducing calf mortality), (4) preventing cutting of productive cows and (5) starting to implement reproductive biotechnology on Bali cattle [5]. The success of reproductive technology implementation requires knowledge regarding estrus cycle of Bali cattle and the ability to detect estrus.

The productivity of beef cattle can be increased by improving reproduction efficiency, in which by increasing calf birth, shortening calving interval, increasing production period and optimize the management of artificial insemination (AI) program. Cattle are polyestrous animals and display estrus behavior approximately every 21 days. The estrus cycle is regulated by hypothalamus hormone (gonadotropin-releasing hormone: GnRH), anterior hypophysis

(follicle-stimulating hormone: FSH and luteinizing hormone: LH), ovarium (progesterone: P4, estradiol: E2 and inhibin) and uterus (prostaglandin F2 α : PGF). These hormones act through positive and negative feedback system to regulate the estrus cycle of cattle [6].

In artificial insemination program, proper estrus detection can increase reproduction efficiency to 50-90%. Estrus signs in cows: anxious, often screaming, mounting and mounted by other cows, vulva: swelling, red, warm to palpation, clear mucus discharge and reduced appetite. The most straightforward sign is when a cow is mounting other cows [7].

There are three stages of estrus, and each stage has several signs as follows: 1. Early estrus stage (< 6-10 hours). Smelling each other, try to mount each other but refusing to be mounted, vulva started to swell and enlarge, resting their chin to the rump of other cows. 2. Standing heat (< 18 hours). The cows will stay when mounted, bellowing more often, hold milk (rubbing udder), rubbing back, and mucus discharge is found in the vulva and tail area. 3. The end of heat stage. The cows will not stay if mounted, shouldering and smelling other cows, and a substantial amount of mucus discharge around the tail and tail bone. In the non-pregnant cow, a normal cycle of estrus occurs every 18-24 days. Usually,

cows that exceed cycle length has calved or has problems in their reproductive system¹⁰. Estrus in cattle occurs 8-30 hours, marked by the acceptance of bulls for copulation. In this phase, the estrogen level reached maximum. High estrogen level causes the emergence of estrus signs, increased contraction of reproductive tract important for sperm and ovarium transportation. Estrogen also influences the amount and type of fluid produced by fallopian tube, uterus, cervix, and vagina [7].

Estrogen hormone highly affects the profile of cervical fluid. The amount and rheological property of cervical mucus is determined by estrogen and inhibited by progesterone [7]. The hormonal system that highly affects estrus is centered on gonadotropin hormone from the anterior hypophysis and ovarian hormone in the form of estrogen and FSH. Changes in FSH and estrogen in the blood causes physiological changes of the body manifested by physical changes of a substantial amount of mucus and changes in mucus composition [8].

High estrogen level in blood during estrus causes higher blood vessel tissues according to the development of the 17 reproductive tracts. In the same time, estrogen increases blood flow to reproductive tracts, thus can trigger cervix

to secrete mucus in excessive amount. Estrogen hormone that acts in female genitals will increase the secretion of cervical mucus. Hormonal factors are highly influential in the middle of follicle development, and the most important hormones are FSH and LH [8]. FSH acts in stimulating ovarium follicle, thus ovarium develops and follicle size increases [7]. Luteinizing Hormone stimulates mitosis and differentiation of granulosa cells and theca cells and induces the development of matured ovum [8]. One of the most important hormones in the estrus cycle is estrogen. Estrogen is one of reproductive steroid hormone. The synthesis of estrogen occurs in theca cells and ovarium granulosa cells which will affect the amount and rheological property of cervical mucus.

This study was aimed to determine the changes in external genitals during estrus and determine estrogen level during estrus in order to correctly determine estrus period by observing changes on external genitals and compare it with estrogen level during estrus. This study is expected to be used in the implementation of reproductive technology in the effort of increasing reproduction efficiency.

II. MATERIALS AND METHODS

Study Design

This study is an analytical observational study with cross-sectional design with the consideration of no intervention from the author, only observing the phenomenon that can be observed and the study was conducted in this period within certain times.

Samples.

The samples used in this study were Bali cattle during estrus. The samples had healthy status without any signs of disease.

Tools and Materials

The tools used in this study were vacutainer tube, 18G needle, needle holder, washer 420 (Biomerieux), ELISA reader 470 (Biomerieux), 37°C incubator, 10-100-micron adjustable pipette (Efordorf), 20-200-micron adjustable pipette (Efordorf), 1000-micron fixed pipette, printer. The materials used in this study were bovine serum, Bovine Estrogen Elisa KIT (Lot. 201307).

Procedure

The blood sample was collected through the jugular vein. The blood was contained in tube without anticoagulant, then let still for 15 minutes, then centrifuged at 3000-4000 ppm for 15-20 minutes to obtain serum. Obtained serum was stored at -20°C until estrogen hormone level assessment is performed.

Determination of Estrogen Hormone Level

The principle of hormone level calculation is similar to Direct Elisa, Double Antibody Sandwich (Merk Cusabio Lot 201307). The determination of hormone level was performed by using the formulation of $y = ax + b$ from absorbent and standard level.

y = absorbance
a = slope
b = intercept
x = level

Changes in External Genital

Estrus observation is conducted twice daily, every morning (06.00-09.00 AM) and afternoon (4.00-6.00 PM). Observing external genital, including changes in vulva and vagina color, swelling in vulva, changes in vaginal temperature and mucus accumulated in vagina, urination, raised the tail and ready to accept male [7].

Data Analysis

Data were analyzed using SPSS for Windows version 20, including normality test with Kolmogorov-Smirnov,

homogeneity test with Levene's Test. Descriptive analysis was used to determine changes in external genital and estrogen level during estrus.

Time and Location of Study

Blood sample of Bali cattle was obtained in several integrated farming systems (SIMANTRI) in Mengwi, Badung. The hormonal assessment was performed in Veterinary Reproductive Laboratory, Faculty of Veterinary Medicine, Udayana, Denpasar. This study was conducted from July to September 2019.

III. RESULTS AND DISCUSSION.

Estrogen Level of Bali Cattle during Estrus

The average estrogen level of Bali cattle during estrus is presented in Table 1. Meanwhile, the changes in external genital are shown in Figure 2.

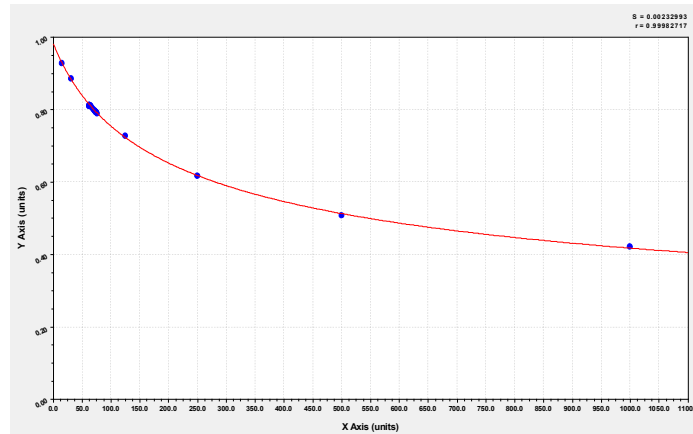


Figure 1. Graph of Estrogen Level during Estrus in Bali Cattle

Table 1. Estrogen levels of Balinese cattle on Estrus (pg / ml)

No. Sampel	Optical Density	Estrogen (pg/ml)
1	0.8127	63.16
2	0.7931	74.23
3	0.8024	68.85
4	0.7927	74.47
5	0.7935	73.99
6	0.8127	63.16
7	0.7932	74.17
8	0.7921	74.83
9	0.8115	63.81
10	0.8095	64.90
11	0.8078	65.83
12	0.7975	71.65
13	0.8085	65.45
14	0.7967	72.12
15	0.7895	76.39
Mean of Estrogen Levels		69.80 pg/ml
SD		4.92

According to OD value shown in Table 1, the estrogen level during estrus in Bali cattle in several SIMANTRI in Mengwi, Badung was obtained. The lowest level of estrogen was 63.16 pg/ml,

Changes in External Genital during Estrus in Bali Cattle

The changes in external genital during estrus can be seen in Figure 1. The

and the highest was 76.39 pg/ml, with an average of 69.80 pg/ml. The estrogen level during estrus in the graph is shown in Figure 1, whereas the Y-axis is the optical density and X-axis is estrogen level.

changes in external genital were observed twice daily, i.e. in the morning (06.00-09.00 AM) and afternoon (04.00-06.00 PM) in several SIMANTRI in Mengwi, Badung.

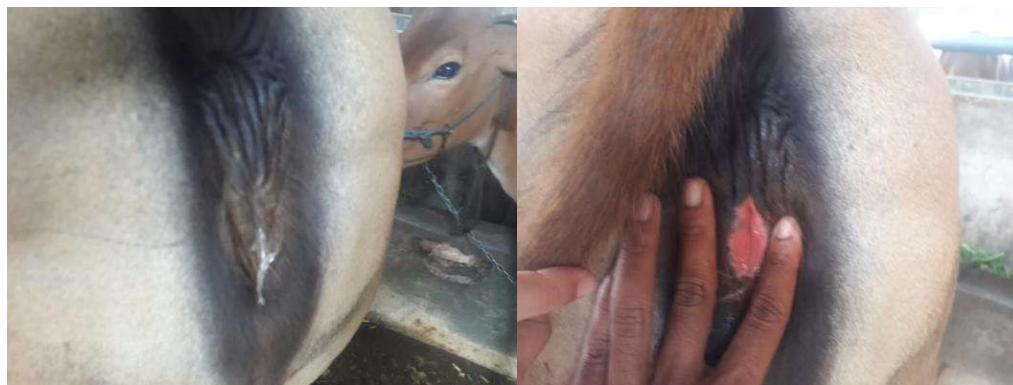


Figure 2. Changes in External Genital during Estrus in Bali Cattle

Figure 2 showed the signs of cows during estrus, i.e. redness on the vaginal mucosa, swelling on the vagina and clear mucus dripping from the vagina.

Discussion

One of the most important hormones in estrus cycle is estrogen. Estrogen is a reproductive steroid hormone. The synthesis of estrogen occurs in theca cells and ovarium granulosa cells which will affect the amount and rheological property of cervical mucus. Estrogen is a hormone responsible for the manifestation of estrus signs. Estrogen is produced by cells that create follicle wall. The external cell layer consists of theca cells, while the inner cells consist of granulosa cells. Both cells produce estrogen. Theca cell bond luteinizing hormone (LH) and produces androgen converted to estrogen by granulosa cells stimulated by FSH [8].

When the estrogen level increases and released to the blood vessel and reached the anterior pituitary, then estrogen will give positive feedback, stimulating the release of LH. Estrogen also affects the nervous system, which causes anxiety and willingness to be mounted by other cows. Estrogen causes the uterus to contract and allowing sperm to be transported through the female reproductive tract after insemination. Other effects of high concentration of estrogen are the increase of blood flow to the genitals and produce mucus by cervical glands and vagina. These characteristics are all signs of estrus. Estradiol hormone stimulates the thickening of the vaginal wall, increasing vascularization; thus external genital experiences swelling and redness and increasing vaginal secretion, thus marked by mucous hanging on the vulva or sticking to the surroundings [8].

Changes in vulva color of local sheep correlate with estrogen hormone that tends to increase during the estrus phase. The statement is in accordance with a statement that estrogen stimulates the thickening of the vaginal wall, increasing vascularization, thus external genital experiences swelling and redness and increasing vaginal secretion, marked by mucous hanging on the vulva or sticking to the surroundings [8]. The increase of estrogen level is correlated to vulva redness and swelling during estrus, which stimulates blood flow to the reproductive tract and related genital organ. High estrogen level during the estrus of local sheep causes the increasing number of blood vessel according to the development of the reproductive tract. At the same time, estrogen increases blood flow to the reproductive tract [9].

In cattle, estrus occurs within 8-30 hours, marked by the acceptance of male for copulation. During this phase, the estrogen level reached maximum. High estrogen level causes the emergence of estrus signs, increases the contraction of reproductive tract important for transportation of sperm and ovum. Estrogen also affects the amount and type of mucus produced by fallopian tube, uterus, cervix, and vagina. During estrus, granulosa cells also release inhibin, which

is a hormone that inhibits the release of FSH from anterior hypophysis [6].

Estrogen level of Bali cattle during estrus after the administration of 100 µg/ml leptin was 80.7 ng/L [10]. Estrogen level during estrus in Bali cattle after the administration of buserelin (GnRH agonist) was 108.33 –111.67 pg/ml. The difference in estrogen level during estrus can be caused by changes in observation on estrus signs and treatment given [11].

Steroid hormone in the ovary holds a vital role in the growth and differentiation of reproductive tissues. Androgen, especially androstenedione and testosterone, is produced by the ovarian theca cells in response to LH. One of the important roles of androgen in ovary is the synthesis of estrogen. All factors affecting androgen and estrogen in ovary can decrease the expression of this hormone receptor, thus can affect the function of ovary and fertility [12]. The effect of estrogen in regulating reproductive function directly related to the cycle of the reproductive hormone. Estrogen in hypothalamus is needed to stimulate the release of GnRH, which triggers LH secretion pattern [13].

The intensity of estrus or estrus expression degree consists of signs that differentiate estrus showed by cows. Estrus intensity category 2 (++) consists of

anxiety, red, slightly swelling vulva with transparent mucus. Meanwhile, estrus intensity category 3 (+++) consists of anxiety and increased bellowing, especially at night, red, slightly swelling vulva and transparent mucus from the vulva region. Estrus behavior will be actualized through estrus intensity, and the condition depends on the concentration of estrogen secreted by follicle de Graaf during estrus [14].

Common estrus signs include mucous discharge, changes in vulva condition (red, swelling, and wet), anxiety and decreased appetite, mounting and mounted. Not all estrus cattle show every sign of estrus with similar intensity or level. The intensity of estrus is determined by estrus intensity score of 1 to 3, in which score 1 (uncertain estrus), score 2 (moderate intensity estrus), and score 3 (estrus with clear intensity). Estrus intensity of score one (1) is given for cattle that showed less mucous discharge (++) , uncertain vulva condition (swelling, wet and red) (+), appetite decrease not apparent (+) and lack of anxiety and no signs of mounting and mounted by other cows (-). Estrus intensity with score two (2) is given to cattle which showed all above estrus signs with ++ symbol, including the signs of mounting other cows, and stayed when mounted by other cows with moderate intensity.

Meanwhile, the intensity with score 3 (clear) is given to cows who clearly shows all signs of estrus (+++) [15].

Usually, estrus detection is conducted by observing cattle behavior and vulva condition. The signs of cows in heat include redness in the vulva, slight swelling and warm vulva, anxiety, raised the tail, and cows in heat rarely graze. The key in determining that the cows that mount each other are currently in heat is the cow that stays still when mounted with reduced appetite [16].

Estrus cycle in cattle occurs in 18-21 days. Estrus observation is one of the important factors in managing cattle reproduction. Factors affecting estrus cycle are age, feed, care system and environment. Estrus detecting is performed at least twice a day, in the morning and the afternoon/evening. Estrus in cattle in the afternoon to morning reached 60%, while from morning to afternoon reached 40 [6]. Estrus with unclear or moderate-intensity is more often caused by individual factors that may be more related to hormonal patten, especially estrogen level that acts in stimulating estrus[16].

Ovarium produces estrogen hormone, which has an important role in estrus intensity. This estrus behavior is affected by estrogen hormone that highly affects the emergence of estrus symptoms. Estrus

is the most important phase in the estrus cycle because, during this phase, the cows are willing to accept males for copulation. Whereas during estrus, estradiol from matured follicle de Graaf causes maximum changes in tubular reproductive tract. The acceptance of males during estrus is caused by the effect of estradiol in the central nervous system, which produces a specific behavioral pattern in female animals [8].

IV. CONCLUSION

According to the results of this study, the estrogen level of Bali cattle during estrus was 69.80 pg/ml. The changes in external genital during estrus found were redness on the vaginal mucosa, transparent mucous discharge, and swelling on the vulva. Further studies should be conducted to determine the quality of ovulation after estrus, whether ovulation follows estrus.

V. ACKNOWLEDGEMENT

The author acknowledges the Dean of the Faculty of Veterinary Medicine, Udayana University through PNPB funding and the Head of Veterinary Reproduction Laboratory who facilitated this study and other parties who helped in the process of this study.

REFERENCE

- [1] Alit IB. 2009. Peluang dan Tantangan Pengembangan Sapi Bali Menuju Komoditas Andalan Nasional. Makalah dalam Seminar Nasional dan Lokakarya menyambut Dies Natalis UNUD. Denpasar 5 Oktober 2009.
- [2] Winaya A, Rahayu ID, Amin M, Herliantin H. 2011. The Genetic Variation of Bali Cattle (*Bos javanicus*) Based on Sex Related Y Chromosome Gene. *Animal Production*, 13(3).
- [3] Bamualim A, Wirdahayati RB. 2003. Nutrition and management strategies to improve Bali cattle productivity in Nusa Tenggara. In *ACIAR PROCEEDINGS* (pp. 17-22). ACIAR; 1998.
- [4] Yupardi WS. 2009. Sapi Bali "Mutiarra dari Bali". Udayana University Press.
- [5] Pusat Kajian Sapi Bali. 2012. Sapi Bali Sumber Daya Genetik Asli Indonesia. PKSB Universitas Udayana. Udayana University Press. Denpasar.
- [6] Hansel W, Convey EM. 1983. Physiology of the estrous cycle. *Journal of Animal Science*, 57(suppl_2), 404-424.
- [7] Hafez ESE, Hafez B. 2000. Reproduction in Farm Animals. 7th Ed. Lippincott William & Wilkins. A Wolters Kluwer Company.
- [8] Toelihere MR. 1993. Fisiologi Reproduksi Pada Ternak. Penerbit Angkasa. Bandung.
- [9] Hafizuddin, Tongku N, Siregar Akmal M. 2011. Hormon Dan Perannya Dalam Dinamika Folikuler Pada Hewan Domestik. *JESBIO* Vol. I No. 1.
- [10] Laksmi DNDI, Pemayun TGO, Damri yasa IM, Dharmawan NS. 2016. Administration of Leptin Increased Concentration of Estrogen and Accelerate the Emergence of Estrus

- in Post Partum Anestrus of Bali Cattle. *Global Veterinaria* 17 (5) : 482-486
- [11] Suartini NK, Trilaksana IGNB, Pemayun TGO. 2013. Kadar Estrogen dan Munculnya Estrus Setelah Pemberian Buserlin pada Sapi Bali yang Mengalami Anestrus Postpartum Akibat Hipofungsi Ovarium. *Jlmu dan Keswan*. 1 (2): 40-44.
- [12] Cavalcante FS, Aiceles V, Ramos CF. 2013. Leptin Regulates Gonadotropins and Steroid Receptors In The Rats Ovary *Nutr Hosp.*;28(1):164-16
- [13] Gao Q, Horvath TL. 2008. Cross-Talk Between Estrogen and Leptin Signaling in The Hypothalamus. *Am J Physiol Endocrinol Metab*294: E817–E826.
- [14] Yoshida C, Nakao T. 2005. Response of Plasma Cortisol and Progesterone after ACTH Challenge in Ovariectomized Lactating Dairy Cows. *Journal of Reproduction and Development*, Vol.51, No. 1.
- [15] Yusuf M, Nakao T, Yoshida C, Long ST, Fujita S, Inayoshi Y, Furuya Y. 2010. Comparison in effect of Heatsynch with heat detection aids and CIDR-Heatsynch in dairy heifers. *Reprod. Dom. Anim.* 45,500- 504.
- [16] Petrus K, Nurcholidah S. Tampilan Berahi dan Tingkat Kesuburan Sapi Bali Timor yang Diinseminasi (The Performance of Estrus and Fertility Rate of Timor Bali Cow Inseminated). *Jurnal Ilmu Ternak*, Juni 2007, Vol.7 No. 1,1-5.