

TUBERCULUM SELLAE MENINGIOMA Vs. MACROADENOMA: How to differentiate preoperatively?

Mardjono, I., Arifin, M. Z., Sidabutar, R., Singh, A., and Sevline, E. O.

Department of Neurosurgery, Faculty of Medicine Universitas Padjadjaran–Dr. Hasan Sadikin
General Hospital, Bandung-Indonesia

Objective: Sellar region tumors may origin from a various number of structures and each of them have a specific clinical and radiological appearance. Among these pathological processes, one of the most challenging is to distinguish between tuberculom sellae meningioma (TSM) and macroadenoma hypophysis (MH). Differentiating these two entities preoperatively is very important to decide which approach will be most suitable and beneficial. The purpose of this study is to produce a simple preoperative scoring system to differentiate these two that can be applied in specific conditions where MRI is not available or could not be performed. **Methods:** This analytical retrospective cohort study contains data obtained from patients treated in Neurosurgery Department of Dr. Hasan Sadikin General Hospital-Bandung from 1 January 2008 until 31 December 2010. There were 34 patients enrolled in this study, in which 15 of them were diagnosed with MH and 19 patients diagnosed with TSM confirmed with pathology examination. **Results:** From clinical presentation we found that the event of endocrinopathy occurs significantly in macroadenoma hypophysis ($p=0.002$). Whereas from radiological evaluation there were 7 parameters that significantly distinguish these two entities including hyperostosis, sellar floor configuration, homogeneity of mass, contrast agent enhancement, waist configuration, peritumoral edema, and dural attachment. From these findings, we propose a simple scoring system to differentiate macroadenoma hypophysis and tuberculom sellae meningioma with a 84.2% sensitivity and 100% specificity. **Conclusion:** although MRI is the modality of choice in differentiating macroadenoma hypophysis and tuberculom sellae meningioma but our scoring system can be used as an aid in choosing best surgical approach.

Keywords: sellae, region tumour, macroadenoma hypophysis, tuberculom sellae meningioma.

INTRODUCTION

Neurosurgery came to developing countries over a half a century ago, yet the vast majority of population in these countries do not have equity in access to it, owing to the cost of neurosurgical care and geographical isolation of patients. Many biomedical equipments such as CT (computed tomography) scan and MRI (magnetic resonance imaging) are not available to most of the population in these countries.¹

The examination of choice in pituitary and sellar region tumors is MRI, because it depicts the complex anatomy around the sellar wall. Almost 30 pathologic entities occur in this region, and most can be distinguished using MRI.² Sellar region tumors are one of the most challenging tumor cases

for neurosurgeons. Two of the most common entities that should be distinguished because of their similarities especially in imaging studies are tuberculom sellae meningioma and macroadenoma hypophysis.³ Preoperative distinction of these tumors is important for best surgical approach. Tuberculom sellae meningioma is usually operated by craniotomy approach, whereas macroadenoma hypophysis uses trans sphenoidal approach.^{4,5}

We propose a simple scoring system based on clinical and radiological evaluation using CT scan that can be used as an aid for determining surgical strategy in cases where MRI could not be performed.

METHOD

This retrospective cohort study consists of 34 patients with sellar region tumors treated and operated in neurosurgery ward of Dr. Hasan Sadikin General Hospital Bandung from 1 January 2008 until 31 December 2010. After the patients received a full verbal and written explanation of this procedure, all provided informed consent. Pathological confirmation showed 15 of these patients diagnosed with macroadenoma hypophysis

Correspondence: Mardjono, I.
Address: Department of Neurosurgery, Faculty of Medicine Universitas Padjadjaran–Dr. Hasan Sadikin General Hospital. Jl. Pasteur No, 38, Bandung 40161, West Java, Indonesia
Phone: +6222 2041694, Fax : +6222 2041694,
Email: joy_mardjono@yahoo.com

and 19 patients with tuberculom sellae meningioma. Data collected included clinical presentation and various characteristics based on CT scan imaging.

Data were processed on a personal computer by using commercially available statistic software. These variables were compared using t test with p value ≤ 0.05 . Only significant variables were then summarized into a scoring system and then tested for its specificity and sensitivity.

RESULTS

From 34 patients in our study, there were 12 male and 22 female patients with average age slightly higher in tuberculom sellae meningioma group (Table 1). As shown below, there is significant correlation of endocrine abnormalities

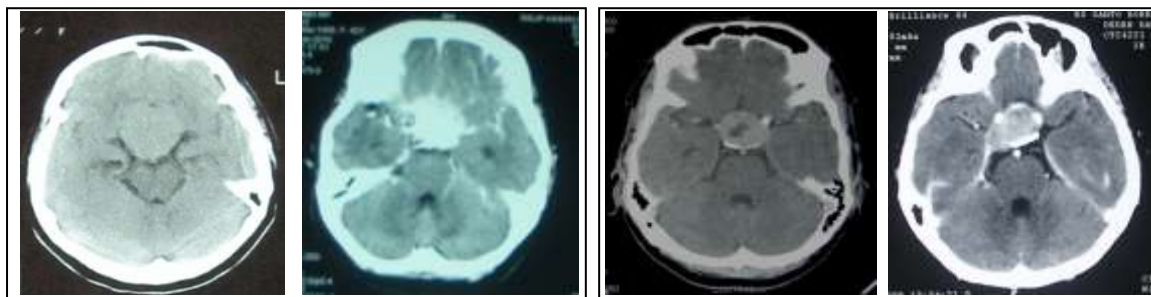
($p=0.002$) in macroadenoma hypophysis. Whereas there is no significant correlation between sex, age, duration of symptoms, tumor size, chief complaint and visual field defect.

Based on radiological findings shown on CT scan, there were certain characteristics that we analyzed to differentiate these two entities (Figure 1 and 2). There is significant correlation of various radiological presentations such as homogeneity on CT scan ($p=0.017$), contrast enhancement ($p=0.001$), hyperostosis ($p=0.002$), thinning of sellar ($p<0.001$), presence of edema ($p=0.004$), size of the sellar waist ($p=0.007$) and alsodural attachment ($p<0.001$) of tumors originating as macroadenoma hypophysis or tuberculom sellae meningioma (Table 2).

Table 1
Clinical Presentation of Patients Diagnosed with Macroadenoma hypophysis (MH) and Tuberculom Sellae Meningioma (TSM)

Variables	MH (n=15)	TSM (n=19)	p
Sex			0.051*
Male	8	4	
Female	7	15	
Age (SD) (year)	35.80(8.02)	39.84(5.78)	0.097**
Tumor size (SD) (cm)	3.74(1.53)	3.62(0.86)	0.777**
Duration of symptoms (SD) (year)	2.24(2.17)	1.83(1.64)	0.539**
Clinical symptoms			0.098*
Headache	6	3	
Visual Loss			0.009*
Negative	8	1	
Unilateral	3	7	
Bilateral	4	11	
Visual field defect			0.397*
No defect	8	7	
Hemianopia Bilateral	4	8	
Hemianopia Unilateral	3	4	
Endocrine abnormalities			0.002**)
Positive	11	4	
Negative	4	15	

*Chi square Test **Mann Whitney test



A Tuberculom sellae meningiomas

B macroadenoma hypophysis

Figure 1

Tuberculom sellae meningiomas appear distinctively homogeneous and enhance entirely after application of contrast. On the contrary, macroadenoma hypophysis have various CT appearance with minimal contrast enhancement

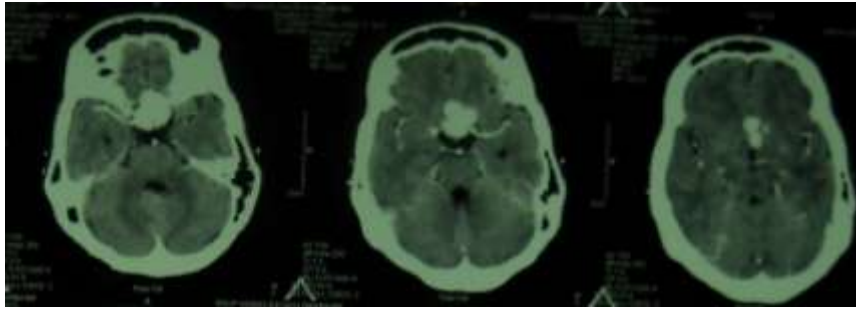


Figure 2

CT Scan of a 44 Year Old Lady Diagnosed with Tuberculom Sella Meningioma.

Note the homogenous enhancement and lobulated configuration but no hiperostosis of the bone is present.

Table 2
Comparison of Radiological Presentation on CT Scan between
Macroadenoma Hypophysis (MH) and Tuberculom Sella Meningioma (TSM)

Variable	MH (n=15)	TSM (n=19)	Total	p	PR (95%CI)
CT appearance				0.001*	2.74(1.37-5.48)
Homogen	2	13	15		
Inhomogen	13	6	19		
CT Enhancement				0.001**	3.60(1.75-7.42)
Minimal	9	1	10		
Bright	6	18	24		
Hyperostosis				0.002**	2.50(1.54-4.04)
Negative	15	10	25		
Positive	0	9	9		
Thinning				<0.001**	5.75 (2.36-14.01)
Negative	4	19	23		
Positive	11	0	11		
Sellar Enlargement				<0.001**	7.53 (1.15-48.84)
Negative	4	16	20		
Positive	11	3	14		
Waist				0.008*	2.63(1.10-6.24)
Negative	5	15	20		
Positive	10	4	14		
Peritumoral Edema				0.004*	2.36(1.50-3.70)
Negative	15	11	26		
Positive	0	8	8		
Attachment				<0.001*	-
Negative	15	0	15		
Tuberculom	0	13	13		
Diaphragm	0	6	6		
Mass Shaped				0.442	1.38 (0.56 – 3.44)
Round	16	11	27		
Lobulated	3	4	4		

*Chi square Test **Mann Whitney test

Table 3
Scoring System of Various Variables to Differentiate between
Macroadenoma Hypophysis and Tuberculom Sella Meningioma

Variable	PA (n=15)	TSM (n=19)	p	Se	Sp	PPV	NPV
Score			<0.001*				
>3	0	16		84.2%	100%	100%	83.3%
≤3	15	3					

*Chi square Test

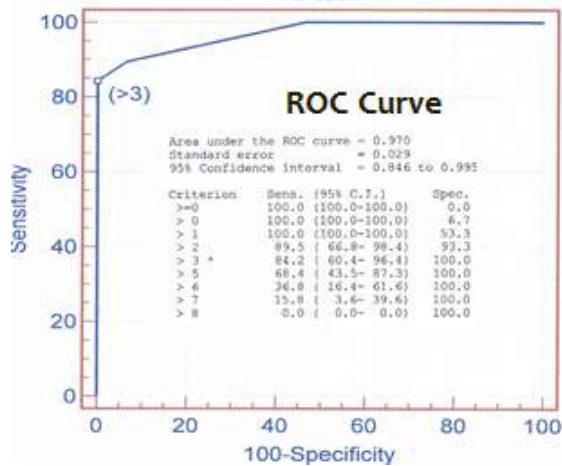


Figure 3

ROC curve showing cut off point of 3 in determining our scoring system.

DISCUSSION

The sellae tursica which resembles a Turkish saddle if viewed from the side, forms a semicircular, central depression within the sphenoid bone. The antero-superior edge of the sella is marked by a horizontal ridge, the tuberculum sellae.⁶ Two of the most frequent pathological process found in this region are macroadenoma hypophysis and tuberculum sellae meningioma.^{3,7} Although according to previous reports the incidence varies according to age, gender and ethnic group. In our series we found predilection for meningioma higher in female patients with average age of 40 years old.⁷⁻⁹

There were three most common symptoms in our report; headache, visual disturbance and endocrinopathy (Table 1). Although almost 70% of our patients complained of visual loss in either of these tumors, they were not significant in this data. In some series, greater than 95% of patients suffer visual acuity and/or field deficits and the pattern of vision loss can vary.⁷⁻¹⁰ In our series, diabetes, we observed that insipidus occurrence was the highest endocrine abnormality present in macroadenoma hypophysis. This stalk compression effect was interestingly also present in 4 patients with tuberculum sellae meningioma.^{9,11}

The gold standard for imaging is MRI as detection rate varies in the literature from 65% to more than 90% for microadenomas but compute tomography and MRI are equivalent in detecting the full extent of a macroadenoma.^{9,11,12} One of imaging studies that is CT scan still has a role in preoperative planning, particularly in regard to pneumatization and the anatomy of the sphenoid sinus as not all neurological centres have MRI facilities.²

In our study, we found seven radiological criteria to help recognize these two entities. Macroadenomas have variable appearances

because they tend to have necrosis, cyst formation, and hemorrhage that appear as mixed attenuation. Curiously there were 6 patients with tuberculum sellae meningioma that show inhomogeneous of mass and 1 patient showing minimal enhancement after contrast administration. Macroadenoma hypophysis are soft tumors which usually indent at diaphragm sellae, giving them a 'snowman' configuration. This is one feature that can help to distinguish between a pituitary macroedema and a meningioma.^{2,9} In our report, 10 out of 15 patients showed a positive waist configuration and also 4 patients of tuberculum sellae meningiomas also had feature.

There was more than 50% of tuberculum sellae meningioma that did not show signs of hyperostosis (10 patients) nor peritumoral edema (11 patients) which are usually characteristics for this type of tumor (Table 2). Adjacent hyperostosis, is the best seen on CT, is present in more than one third of cases and is a helpful sign in meningiomas.^{12,13} In some previous reports, the sellae tursica is usually not expanded or only slightly enlarged in tuberculum sellae meningiomas. This is in accordance to our report where 3 patients with tuberculum sellae meningiomas had sellar enlargement, in contrast to macroadenoma hypophysis (11 patients).^{9,11}

Sellar floor thinning or erosion are other criteria that could be useful in diagnosing macroadenoma hypophysis. Eleven patients with macroadenoma hypophysis showed sellar floor thinning but there were 4 cases that did not have this feature. Obtuse dural margins and dural tail enhancement of lesions involving the sella, are helpful in the preoperative diagnosis.¹² Most of the specific CT scan features that we analyze in our series, showed significance in helping to diagnose macroadenoma hypophysis and tuberculum sellae meningioma.

After analyzing various variables in determining difference in the two types of tumors, we can state that there were eight variables demonstrating significance ($p < 0.05$) such as; endocrine abnormalities ($p = 0.002$), hyperostosis ($p = 0.002$), thinning of sellae ($p < 0.001$), waist configuration ($p = 0.008$), peritumoral edema ($p = 0.004$), dural attachment ($p < 0.001$), CT homogeneity of mass ($p = 0.001$) and contrast enhancement ($p = 0.001$). After analyzing using a ROC (receiver operating characteristic) curve, we found a cut off point of 3 from these variables (Graphic 1). Using our simple method, we came up with a very accurate scoring system to discern between macroadenoma hypophysis and tuberculum sellae meningioma (Table 3). This scoring system has a p value of < 0.001 with sensitivity of 84.2% and specificity of 100%. We measured the PPV (positive predictive value) is

100% and NPV (net present value) is 83.3% with accuracy of 94.1%.

Applying our simple method we can help to diagnose these two entities. It is important to differentiate tuberculom sellae meningioma from the macroadenoma hypophysis, because craniotomy is done for meningioma, whereas a transsphenoidal route is preferred for most macroadenoma hypophysis.^{3,4,11,14} Transsphenoidal surgery is the approach of choice for macroadenoma hypophysis.¹⁵ Tuberculom sellae meningiomas usually have a firm, rubbery consistency and often require sharp dissection rather than simple suctioning for their removal.¹¹ Based on our preference, all of our patients diagnosed with tuberculom sellae meningioma were operated using a pterional approach.

CONCLUSION

In conclusion, the superiority and usefulness of MRI is unquestionable as it is the gold standard imaging to distinguish macroadenoma hypophysis and tuberculom sellae meningioma but this modality is often not available in many countries. A simple scoring system can be useful as a tool for preoperative surgical strategy in differentiating these two entities. A score of more than 3 is most likely to be diagnosed as tuberculom sellae meningioma whereas less than 3 is representative for macroadenoma hypophysis.

REFERENCES

1. Black, P. 2007. The future of neurosurgery: a call to leadership. *Clin. Neurosurg.* 54.
2. Khan-Ali. Pituitary Adenoma Imaging. 2011. (Downloaded 4th April 2012) In :<http://emedicine.medscape.com/article/343207-overview#a21>.
3. Kaltsas, G. A., Evanson, J., Chrisoulidou, A., and Grossman, A. B. 2008. The Diagnosis and management of parasellar tumours of the pituitary. *Endocr-Relat Cancer.* 15 (4): 885–903.
4. Rasras, S., Ansari, M. J. A., Ansari, M. H. A., Rahbarian, F., and Rashidi, I. 2012. Diaphragma sellae meningioma mimicking pituitary macroadenoma: a case report. *IJCRIMPH.* 2 (11) : 404.
5. Taylor, S. L., Barakos, J. A., Harsh, G. R., and Wilson, C. B. 1992. Magnetic resonance imaging of tuberculom sellae meningiomas: preventing preoperative misdiagnosis as pituitary macroadenoma. [Neurosurgery.](#) 31(4):621.
6. Schubiger, O. 1996. Radiology of pituitary adenomas in: Landolt, A. M., Vince, M. L., and Reilly P.L, eds. *Pituitary Adenomas.* UK: Churchill Livingstone. p. 177-219,
7. Jagannathan, J., Kanter, A. J., Sheehan, J. P., Jane, J. A. Jr., and Laws, E. R. Jr. 2007. Benign brain tumors: sellar/parasellar tumors. *Neurol Clin.* 25 (4):1231-.
8. Al-Mefty, O., Abdulrauf-Saleem, I., and Haddad-Georges, F. 2012. Meningiomas. In: Winn, H. R., ed. *Youman's Neurological Surgery.* 6th edition. Philadelphia: Elsevier Saunders;. pp 1426-1449.
9. Mc-Vallo, B., and Mc-Cormack, B. 2007. Surgical management of tuberculom sellae and sphenoid ridge meningiomas. In: Schmidek, ed. *Schmidek & Sweet's Operative Neurosurgical Techniques Indications, Methods, and Results.* 4th edition . USA :W.B.Saunders;. pp 305-324
10. Chi, J. H., and McDermott, M. W. 2003. Tuberculom sellae meningiomas. *Neurosurg Focus.* 14 (6): 6.
11. Mulinda, J. 2011. Pituitary macroadenoma. (Downloaded 4th April 2012). In: <http://emedicine.medscape.com/article/123223-clinical>
12. Bowers, C. A., Altay, T., and Couldwell, W. T. 2011. Surgical decision-making strategies in tuberculom sellae meningioma resection. *Neurosurg Focus.* 30 (5): E1.
13. Anderson, J. R., Antoun, N., Burnet, N., Chatterjee, K., Edwards, O., Pickard, J. D., et. al. 1999. Neurology of the pituitary gland. *JNeurol Neurosurg Psychiatry.* 66 (6):703–21.
14. Donovan, J. L., and Nesbit, G. M. 1996. Distinction of masses involving sella and suprasellar space: specificity of imaging features. *Am J Roentgenology.* 167 (3): 597-603
15. Cappabianca, P., Cirillo, S., Alfieri, A., D'Amico, A., Maiuri, F., Mariniello G, et. al. 1999. Pituitary macroadenoma and diaphragm sellae meningioma: differential diagnosis on MRI. *Neuroradiology.* 41 (1): 22-6.
16. Swearingen, B., and Zeevas, N. 2007. Surgical management of Cushing's Disease. In: Schmidek, ed. *Schmidek & Sweet's Operative Neurosurgical Techniques Indications, Methods, and Results* 4th edition. USA: W.B.Saunders. pp 305-324.