

## REVIEW OF NASA FIBROMYXOMA: Aggressive Behaviour? (Case Report)

Rr. Suzy Indharty

Department of Neurosurgery, Faculty of Medicine, Sumatera Utara University/  
Haji Adam Malik Hospital, Sumatra-Indonesia

**Background:** Myxomas are rare benign tumors arising from mesenchymal tissues throughout the body. These tumors are usually seen in the atrium of the heart and the jawbone. Involvement of the skull base with intracranial extension is extremely rare, and only a few cases of primary intracranial myxomas have been described in the literature. This article presents a rare case of primary myxoma of the nasal bone. **Methods:** The patient underwent a skull base surgery with a pre-diagnosis of possible fibromyxomas. The tumor pathology revealed a diagnosis of myxoma with bone and meningeal involvement. Despite the debulking surgery, the tumor showed a local recurrence in five month. A second debulking surgery in piece meal was required. In the article, the etiology, histological and radiological findings as well as treatment options of this rare entity were briefly discussed under the highlights of the relevant literature. Such a localization and intracranial extension of myxomas is extremely unusual in clinical practice; the diagnosis therefore requires a high degree of suspicion and detailed histopathological examination. The differential diagnosis frequently includes chondrosarcomas, chordoma, metastatic tumors of the skull, hemangiopericytoma, meningioma and other neoplasms of the dura and skull base in this location.

**KEYWORDS:** Myxoma, Skull base, Temporal bone, Neoplasm.

### INTRODUCTION

Myxomas are benign tumors of primitive mesenchymal tissue, and are usually found in the heart, skin, certain bones and genitalia.<sup>1</sup> Myxomas are locally invasive, benign mesenchymal neoplasms with odontogenic, osteogenic, or soft tissue origin. Facial myxomas probably account for less than 0.5% of all paranasal sinus and nasal tumors. These tumors may be primary or embolic from an underlying cardiac myxoma. Primary myxomas of the head and neck are rare lesions in clinical practice, and usually involve the maxillofacial skeleton. Myxomas are rare in children under 10 years of age. Although this tumor is reported most frequently in the mandible for the general population, it has rarely been reported in the mandible in children <10 years of age. There are only a few cases concerning primary intracranial myxomas that have been published in the literature. Intracerebral lesions that are metastatic or embolic from cardiac myxomas are more frequent but also uncommon.

### Address for Correspondence

Rr. Suzy Indharty  
Department of Neurosurgery, Faculty of  
Medicine, Sumatera Utara University/Haji Adam  
Malik Hospital, Sumatra-Indonesia  
Email:suindharty@gmail.com

### CASE REPORT

A 3½ years old girl patient initially presented to a neurosurgeon with a complaint of lump in her right nose (Figure 1A). Her olfactory ability is reduced since two months ago. She referred to our hospital with a prediagnosis of intracranial neoplasm documented with a computerized tomography (CT) scan study. CT Scan study revealed an extra axial mass lesion of possible bony origin measuring 53x47x33 mm in diameter. The lesion compressing the nasal cavity with no associated edema was hypointense on CT scan image (Figure 1B). Computed Tomography (CT) studies revealed an enhancing calcified lesion invading the nasal bone and extending to the intra mucosal nasal (Figure 1C). Its expanding nature in the nasal bone with decreased thickness of the inner and outer table was noteworthy. She underwent debulking surgery (Figure 1D) by neurosurgeons with a prediagnosis intranasal tumor that differential diagnosis with squamous cell carcinoma and angiofibroma.

### First Surgical Procedure

A skull base approach with lateral rhinotomy was used. The mass of the left meatus nasi, Lateral incision rice dextra. Tumor intra nasal mucosa, Pus (+), some part of mass suctionable, hipervaskuler, well capsulated, debulking were determined. Part nevus with intracranial could not be determined. Discontinued operations planned two stages depending on the results PA. The tumor was

composed of elastic, fibrous stroma and soft, mucoid islands scattered throughout the eroded bony cavities resembling a honeycomb pattern. With intracranial involvement cannot be ascertained. The tumor was removed by debulking slowly using a microscope.

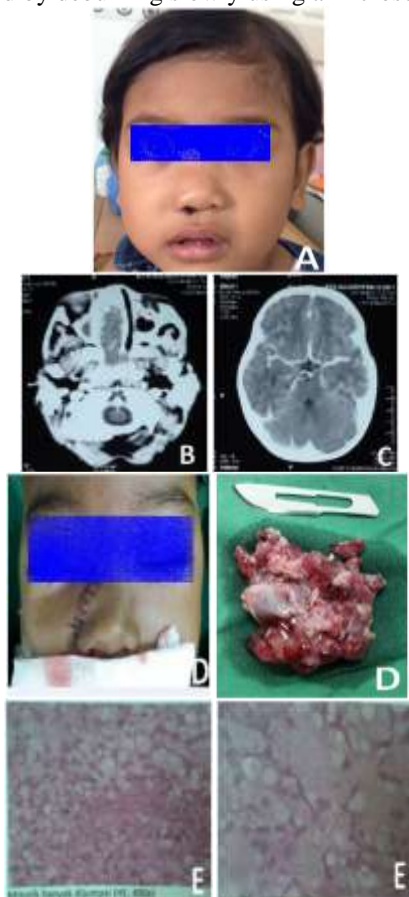


Figure 1

- A) a 3½ years old girl with a lump in hers right nose;  
 B) axial CT scans of the brain shows an enhancing mass lesion arising from the nasal bone; C) the tumor expands the nasal bone and extends to the intra mucosal nasal; D) the mass of the right meatus nasi. lateral incision rice dextra tumor intra nasal mucosa, hipervaskuler, well capsulated, debulking;  
 E) core shape stellate and spindle, basophilic chromatin, cytoplasm many partly clear, partly eosinophilic, and partly immersed in strom which mixoid.

### Histological Finding

The tumor preparations derived from the nose portion edges coated by several layers of cells-flat epithelial cells and cell proliferation appear - fibrous cells around the edge and in the middle bundle of tumor tissue, the spindle core, chromatin basophilic, eosinophilic cytoplasm, N/C ratio is within normal limits. Most of the cell - the tumor cells arranged loosely, with the core shape stellate and spindle, basophilic chromatin, cytoplasm many partly clear, partly eosinophilic, and partly immersed in strom which miksoid (Figure 1E). Histopathological examination revealed a diagnosis of sinonasal

myxoma or fibromyxoma. She was advised to attend regular follow-up after the surgery.

### Follow-up Examination

At the five months follow up, this girl came back with raised bump on the nose the size of 55x47x38cm, touch chewy, and hyperemia, there is a necrotic area at the tip of the tumor mass. Patient felt pain on her right eye. On neurological examination we found anosmia and 3, 5, 6, 7 right nerve paralysis. Her radiological screening showed enhancing mass lesion arising from the Nasal bone attachment to the muscles of the face / cheek and maxillary sinus wall. Up to 80% of tumors with tumor on the right retroorbital and fontal were observed (Figure 2A, B).

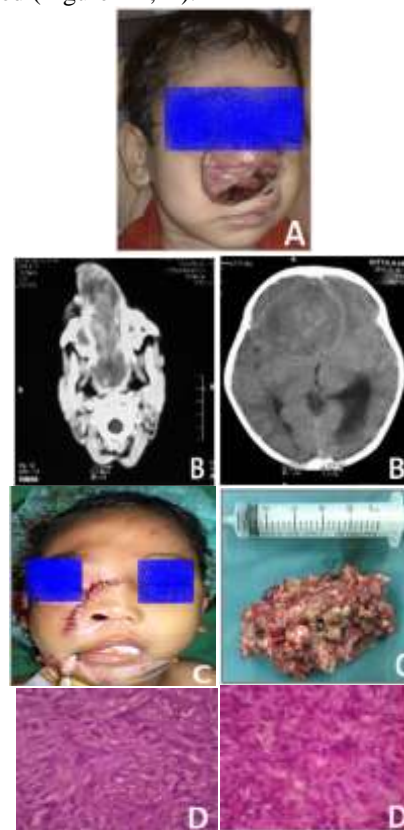


Figure 2

- A) a recurrence in the Right Nose with size 55x47x38mm, touch chewy, and hyperemia, there  
 B) a necrotic area at the tip of the tumor mass. Axial CT scans of the brain show an enhancing mass lesion arising from the Nasal bone attachment to the muscles of the face / cheek and maxillary sinus wall. Up to 80% of tumors with tumor on the right retroorbital and fontal. C) Tumor grey reddish, soft lobulated, fibrous, minimal vascularity attachment to the muscles of the face / cheek and maxillary sinus wall. Up to 80% of tumors with tumor on the right retroorbital and fontal. D) Demonstrate characteristic hypocellular areas of satellite and spindle cells scattered within amyloid matrix and few bone spicules (x100). The absence of polymorphism and mitotic activity is typical.

### Second Surgery

Second Operation was done. Incision design performed on mass tumour. Durante operation seem appropriate tumor mass. Debulking the tumor is done in piece meal, some mass can suck. Tumor grey reddish, soft lobulated, fibrous, minimal vascularity attachment to the muscles of the face /cheek and maxillary sinus wall. Up to 80% of tumors with tumor on the left retro-orbital and frontal. Surgical wound was closed layer by layer. Operation completed (Figure 2B).

### Histological Finding

The histopathological examination was quite similar to those of the first one. The tumor was composed of satellite cells scattered within a mucoid stroma (Figure 2C). The absence of cellularity, cellular pleomorphism and mitosis was remarkable. Immunohistochemistry findings supported the diagnosis of myxoma (positive staining with vimentin and negative with pan-cytokeratin, keratin and S-100).

### Follow-up Examination

After one month operation, this little girl come to our hospital with a complain clear white discharge from the right nose right (Figure 3A). Anosmia and 3,4,5,6,7 nerve paralysis still found. Her radiological screening showed enhancing mass lesion arising from the Nasal bone attachment frontal base (extradura, attached to sinus cavernous + intradura) (Figure 3B).

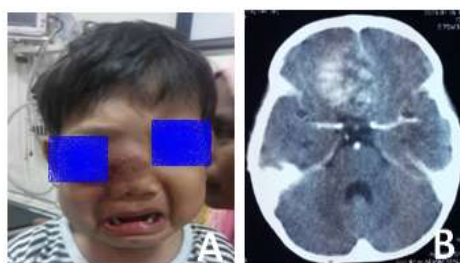

Figure 3

- A) One months recurrence after second surgery.  
B) Axial CT scans of the brain shows an enhancing mass lesion arising from the Nasal bone attachment frontal base (extradura, attached to sinus cavernous + intradura)

### Third Surgery

She underwent a third surgery through the previous route and a debulking surgery with piece meal was carried out (Figure 3C) Incision on Pterional dextra size 15 cm (intracranial: extradura + intradura attack). Lytic bone orbital roof, partially invaded tumors. Some in retroorbita (extradura + intradura), gray reddish, soft, partially suctionable. Some in frontal base (extradura, attached to sinus cavernous + intradura) Gray redish, springy. Total removal intradura, 90% extradural, 10% attached to cavernous sinus left.

### Histological Finding

The histopathological examination were quite similar to those of the second one. The tumor was composed of satellite cells scattered within a mucoid stroma (Figure 3D).

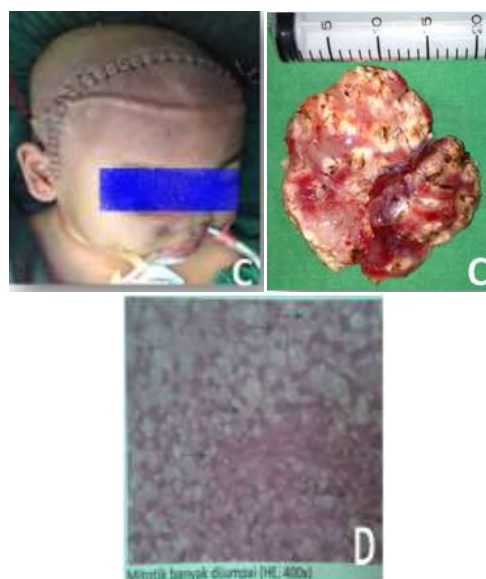


Figure 3

- C) Tumor found in retroorbita(extradura+intradura), gray reddish, soft. Some in frontal base (extradura, attached to sinus cavernous + intradura) Gray redish, springy, total removal intradura, 90% extradural,10% attached to cavernous sinus left.  
D) core shape stellate and spindle, basophilic chromatin, cytoplasm many partly clear, partly eosinophilic, and partly immersed in strom which mixoid.

### Histological Finding

Now the little girl is currently undergoing radiotherapy as much as 21x. It is ironic, nasal fibromyxoma which we know as a benign tumor recurrence rate was found to cause more than once. For a more detailed examination, the results of anatomical pathology of this little girl, we sent to Department of Neurosurgery, Erasmus University Medical Center, Rotterdam and was examined by Prof. Max Kros, neuropathologist in Erasmus MC, and the result suggested a (nasal) myxofibroma. From microscopy, we found tissue fragments with only lesionaal tissue in which a tumor process is seen in a myxomatous background located spindle-shaped cells with a small amount of focus bounded thin elongated nuclei with eosinophilic cytoplasm and a smooth chromatin pattern without prominent polymorphism or polychromasia. No increased division activity (less than 1/10 HPF). There is a slight admixture in a part of the tumor of collagenous connective tissue fibers that break in double polarization. Immunohistochemistry also done with the result S100 negative; Smooth muscle actin: negative (vascular positivity).

### Follow-up Examination

Complaints in girls is now discharge from the nose to the left is reduced. Pain in the right eye is also reduced. But anosmia and nerve paralysis 3,4,5,6,7 remains found.

### DISCUSSION

Myxomas are slow growing, benign neoplasms of mesenchymal origin that may arise in soft tissues and bone throughout the body.<sup>1</sup> They are generally seen in adolescents and adults and more frequently in the mandible and maxilla often associated with missing or impacted teeth.<sup>2</sup> They probably account for less than 0.5% of all paranasal sinus and nasal tumors. Myxoma is a rare tumor in childhood with similar sex incidence.<sup>3</sup> As in our patient they are painless masses that remain undetected for several months.

When symptoms of nasal congestion, epistaxis, or face distortion occur, these lesions commonly have bony erosion.<sup>4</sup> The gross appearance of these tumors appears as smooth, rubbery, and gray-white spherical masses with gelatinous cut surface. The consistency may vary depending on the amount of fibrous tissue. They can simulate encapsulated lesions owing to the compression and condensation of the surrounding tissues but lack a true capsule and are locally infiltrative. The typical histologic appearance is of a hypocellular tumor composed of undifferentiated spindle and stellate cells, arranged in a loose mucoid stroma rich in hyaluronidase.

Myxoma is to be distinguished from a spectrum of reactive and neoplastic lesions that may show prominent myxoid degeneration including nodular fasciitis, schwannomas, neurofibromas, myxoid chondrosarcoma, myxoid liposarcoma, and embryonal rhabdomyosarcoma. Unlike benign myxomas, these sarcomas display areas of increased cellularity, pleomorphism, mitotic activity, and a rich vascular network. Myxoma is unresponsive to chemotherapy and is poorly responsive to radiotherapy. Surgery remains the treatment of choice.<sup>5,6</sup> However, because of the unencapsulated and infiltrative nature of these tumors, extensive surgery is often required to achieve clear resection margins and avoid recurrence. A review of reported cases demonstrated that patients who underwent a complete resection fared well with no recurrence in the short-term follow-up period.

In conclusion myxoma should be considered as a differential diagnosis in children with a painless periocular mass and differentiated from more malignant tumors, such as embryonal rhabdomyosarcoma. The immunohistochemistry is a useful complementary tool to confirm the diagnosis of myxoma and to rule out other benign and malignant myxoid tumors. Complete resection of the tumor with free margins is the treatment of choice.

### CONCLUSIONS

Primary intracranial myxoma should be distinguished from other myxoid intracranial tumors such as myxomatous meningioma, epitheloid hemangioendothelioma or sarcoma through appropriate pathological and immunohistochemical analysis. Nasal fibromyxoma that was considered a benign tumor that turns its rapid growth since the first operation and the impression is not sensitive to radiotherapy. Surgery remains the main treatment and role of radiotherapy is not established but may be given for residual disease.

### REFERENCES

1. DeFatta R. J., Verret D. J., Ducic Y., Carrick K. 2006. Giant Myxomas of The Maxillofacial Skeleton and Skull Base. *Otolaryngol Head Neck Surg.* 134(6):931-935.
2. Veras Filho R. D. O., Pinheiro S. S., deAlmeida I. C. P., Arruda M. D. L. S., and Costa A. D. L. L. 2008. Odontogenic Myxoma of The Maxilla Invading The Maxillary Sinus, *Brazilian Journal of Otorhinolaryngology*, vol. 74, no. 6, p. 945.
3. Arjona Amo M., Belmonte Caro R., Valdivieso del Pueblo C., Batista Cruzado A., Torres Lagares D., Gutiérrez Pérez J. L. 2011. Odontogenic Myxoma of Nasosinusal Localization in a Pediatric Patient," *Cirugía Pediátrica*, vol. 24, no. 2, pp. 118-121.
4. Prasannan L., Warren L., Herzog C. E., Lopez-Camarillo L., Frankel L., and Goepfert H. 2005. "Sinonasal Myxoma: a pediatric case," *Journal of Pediatric Hematology/Oncology*, vol. 27, no. 2, pp. 90-92.
5. Yin H., Cai B. W., An H. M., You C. 2007. Huge Primary Myxoma of Skull Base: A report of an uncommon case. *Acta Neurochir (Wien)*149(7):713-717.
6. Zhang L., Zhang M., Zhang J., Luo L., Xu Z., Li G., Tian Y., Wang Y., Wu Z, Wang Z. 2007. Myxoma of The Cranial Base. *Su.rg. Neurol* 68(suppl 2):22-28.

